

Effects of Autologous Conditioned Plasma® (ACP) on the healing of surgically induced core lesions in equine superficial digital flexor tendon

Roberto J. Estrada^{1,2}, René van Weeren³, Chris H. A. van de Lest^{3,4}, Janneke Boere³, Magaly Reyes⁵, Jean-Claude Ionita⁶, Manuel Estrada², Christoph J. Lischer¹

¹ Equine Clinic, School of Veterinary Medicine, Free University of Berlin, 14163 Berlin, Germany

² Large Animal Hospital, School of Veterinary Medicine, National University, 86-3000 Heredia, Costa Rica

³ Department of Equine Sciences, Faculty of Veterinary Medicine, Utrecht University, 3584 CM Utrecht, The Netherlands

⁴ Department of Biochemistry and Cell Biology, Faculty of Veterinary Medicine, Utrecht University, 3584 CM Utrecht, The Netherlands

⁵ Department of Orthopaedics, Erasmus MC, University Medical Center, 3015 CE Rotterdam, The Netherlands

⁶ Large Animal Clinic for Surgery, Faculty of Veterinary Medicine, University of Leipzig, 04103 Leipzig, Germany

Summary: Tendon pathologies are among the most common musculoskeletal disorders in horses. After damage the tendon repairs by forming disorganized scar tissue that is of inferior functional quality than normal tendon, leading to high re-injury rates. Many of the currently available treatment modalities cannot significantly reduce this high recurrence rate. Autologous Conditioned Plasma (ACP, Arthrex Inc., USA) has been described in the literature as a leukocyte-reduced platelet concentrate. This blood product has been used in equine and human medicine for the treatment of tendon and ligament injuries. However, the effect of this therapeutical approach on tendon healing is unknown. Core lesions were surgically induced in the Superficial Digital Flexor Tendons (SDFT) of both fore- and hindlimbs in eight healthy horses. At days 7 and 15 after lesion induction one randomly assigned fore- and hindlimb was treated with ACP and the contralateral one with saline. This study used data from the forelimbs SDFTs only. Gray-scale and color Doppler ultrasonographic parameters monitored throughout the study didn't differ significantly at any time point. Twenty-two weeks after the last treatment, the ACP treated tendons presented a significantly lower concentration of sulphated glycosaminoglycans (GAGs) ($p \leq 0.05$) when compared to saline. Other compositional, biomechanical and histological parameters presented no significant differences. Our study indicates that 2 intra-tendinous ACP treatments (without anticoagulant) during the proliferative phase of healing in surgically induced tendon core lesions, have a limited effect on tendon healing when comparing ultrasonographic, biochemical, biomechanical and histological parameters with the control treatment. Long-term placebo controlled clinical trials with more horses are warranted to determine if this effect is clinically significant.

Keywords: horse / platelet concentrate / Autologous Conditioned Plasma (ACP) / tendon / healing / model / orthopedics

Auswirkungen von Autologous Conditioned Plasma® (ACP) in der Heilung von chirurgischen induzierten Core Lesions der oberflächlichen Beugesehne des Pferdes

Sehnenerkrankungen gehören zu den häufigsten Erkrankungen des Bewegungsapparates beim Pferd. Nach einer Läsion werden die Sehnen in der Regel durch unorganisierte Bildung von Narbengewebe repariert. Die reparierten Strukturen zeigen eine niedrige funktionale Qualität, was zu einer hohen Wiederverletzungsrate führt. Viele der derzeit verfügbaren Behandlungsmethoden können diese hohe Rezidivrate nicht reduzieren, was eine Fortsetzung der Suche nach verbesserten Therapien vorantreibt. Autologous Conditioned Plasma® (ACP, Arthrex Inc., USA) ist in der Literatur als ein leukozytenreduziertes Thrombozytenkonzentrat beschrieben worden, welches zur Behandlung von Sehnen- und Bänderverletzungen in der Pferd- und Humanmedizin verwendet wurde. Jüngste Studien deuten an, dass diese Therapieform die Sehnenheilung effektiver als andere Thrombozytenkonzentrate fördern könnte. Allerdings ist der Effekt dieses Therapieansatzes auf die Sehnenheilung unbekannt. Daher war das Ziel dieser Studie, die Auswirkungen der intraläsionalen Behandlung von Sehnenverletzungen mit ACP zu bewerten. Bei acht gesunden Pferden wurden an der oberflächlichen Beugesehne (OBS), an beiden Vorder- und Hintergliedmaßen, standardisierte chirurgische Läsionen gesetzt. An den Tagen 7 und 15 nach Induktion der Läsion wurde an je einer Vorder- und Hintergliedmaße unter Ultraschallkontrolle ACP intraläsional injiziert. Die jeweilige kontralaterale Gliedmaße wurde mit steriler Kochsalzlösung behandelt. Für diese Studie wurden nur die Daten der Vordergliedmaßen verwendet. Der Verlauf der Sehnenheilung wurde klinisch und mit Graustufen- bzw. Farbdopplersonographie kontrolliert. Nach 24 Wochen wurden die Sehnenproben für die Bewertung der biochemischen, biomechanischen und histologischen Parametern entnommen. Dreiundzwanzig Wochen nach der Behandlung wiesen die ACP behandelten Sehnen eine deutlich geringere Konzentration an Glykosaminoglykanen (GAG) ($p \leq 0.05$) im Vergleich zur Placebogruppe. Während der Proliferationsphase der Heilung führen intraläsionale ACP-Behandlungen von chirurgisch induzierten „Core Lesions“ der OBS, im Vergleich zur Placebogruppe, zu einem begrenzten Effekt in der Sehnenheilung. Langfristige Placebo-kontrollierte klinische Studien mit einer höheren Anzahl von Pferden sollten durchgeführt werden, um nachzuweisen, ob dieser Effekt klinisch relevant ist.

Schlüsselwörter: Pferd / Trombozytenkonzentrat / Autologous Conditioned Plasma (ACP) / Sehnen / Heilung / Model / Orthopädie

Citation: Estrada R. J., van Weeren R., van de Lest C. H. A., Boere J., Reyes M., Ionita J.-C., Estrada M., Lischer C. L. (2014) Effects of Autologous Conditioned Plasma® (ACP) on the healing of surgically induced core lesions in equine superficial digital flexor tendon. *Pferdeheilkunde* 30, XXX-XXX

Correspondence: Roberto J. Estrada DVM, Large Animal Surgery Residen, Department of Surgery and Orthopedics, Equine Clinic, Free University of Berlin, Oertzenweg 19b, 14163 Berlin, Germany, restrada@zedat.fu-berlin.de

Introduction

Tendon pathologies are among the most common musculoskeletal disorders in horses (Avella et al. 2009, Singer et al. 2008, Murray et al. 2006, Kasashima et al. 2004). After injury the tendon repairs by forming disorganized scar tissue (Birch et al. 1998, Williams et al. 1980), which is of inferior functional quality when compared to normal tendon and therefore prone to re-injury (Crevier-Denoix et al. 1997). Even though some therapeutical approaches have shown promising results (Godwin et al. 2012), many of the currently available treatment modalities cannot significantly reduce these high recurrence rates (O'Meara et al. 2010, Dyson 2004, Gibson et al. 1997).

During the last years the use of autologous blood products for treatment of equine tendon and ligament injuries has increased (Bosch et al. 2010, Waselau et al. 2008). Platelet concentrates seem to be a promising option, as upon thrombocyte granules activation a large number of anabolic growth factors (TGF- β , PDGF-BB, VEGF, etc.) are released. These growth factors are supposed to act as humoral mediators and biological catalysts, promoting tissue healing (Boswell et al. 2012). Moreover, recent studies indicate that platelet concentrates exhibit an important in vitro and in vivo anti-inflammatory effect when used to treat tenocytes exposed to an inflammatory insult and tendon injuries (Zhang et al. 2013).

At the moment there is no consensus as to which platelet concentrate preparation is most efficient for the improvement of tendon healing. There are a variety of preparations featuring different profiles concerning growth factor concentration, kinetics of growth factor release, inflammatory cytokine expression, platelet and white blood cell counts (McCarrel et al. 2012, Sundman et al. 2011). These variations are likely to have an impact on the clinical outcome and hence the effects of specific platelet preparations on tendon healing need to be investigated. Autologous Conditioned Plasma (ACP, Arthrex Inc.) is a leukocyte-reduced platelet concentrate that has been used in equines and humans for the treatment of tendon and ligament injuries (Rindermann et al. 2010, Deans et al. 2012). In vitro studies have shown that ACP allows concentration of platelets and growth factors while at the same time decreasing WBC counts (McCarrel et al. 2012, Kissich et al. 2012). Even though there are conflicting reports about the role that WBC counts in blood products play on tendon healing (McCarrel et al. 2012, Sundman et al. 2011, Everts et al. 2006), several in vitro studies have demonstrated that lower WBC counts in the platelet concentrates are directly correlated to a lower concentration of catabolic enzymes (McCarrel et al. 2012, Sundman et al. 2011). Therefore, it has been suggested that leukocyte-reduced platelet concentrates might be superior than platelet rich plasma (PRP) in stimulating tendon healing, since persistent inflammation incited by the high concentration of WBC may result in scar tissue formation (McCarrel et al. 2012).

The aim of this study was to evaluate the effects of the ACP on healing of standardized surgically induced SDFT core lesions in horses. It was hypothesized that intra-lesional ACP treatments at days 7 and 15 after SDFT lesion induction would improve sonographic, biochemical, biomechanical and histological parameters of the tendons when compared to saline.

Materials and Methods

SDFT lesions affect more often the forelimbs than the hindlimbs, therefore, for this paper, only the results of the forelimbs will be discussed. The data derived from the hindlimbs was used to compare the healing differences between saline treated fore- and hindlimb SDFT core lesions in tendinopathy models (Estrada et al. 2014).

Experimental animals

Eight, mixed breed, 2.5 to 6 year old horses with average weight of 434 (\pm 38) kg were selected. The animals were free of lameness and presented no clinical or ultrasonographic signs of acute or chronic SDFT lesions. Horses were housed in individual boxes, fed a maintenance ration of concentrate with hay and had water ad libitum. This study was approved by the Animal Welfare Committee (Session Nr. 003-10), School of Veterinary Medicine, National University, Costa Rica in accordance to the Costarrican Act 7451 on Animal Welfare.

Lesion induction and postoperative management

Tendon lesions were created under general anesthesia in the SDFT of all fore- and hindlimbs using a modification of the tendinitis model described by Schramme and others (2010). The horses were sedated with xylazine (Procin Equus: Pisa, Mexico) (1,1 mg/kg bwt, i.v.) and then induced using ketamine/midazolam (Ketamid: Holliday, Argentina) (2,2 mg/kg bwt, i.v.). Thereafter, the anesthesia was maintained with isoflurane (Aerrane: Baxter Int., Illinois). A linear array probe (DP 3300 Vet: Mindray, China) covered with a sterile palpation sleeve was used to standardize the incision site just proximal to the digital flexor tendon sheath, in the ecographic zones 3A and 4A, in the fore- and hindlimb, respectively (Rantanen et al. 2011). A 1.5cm skin incision was performed in the selected site using a scalpel blade No.10 and then a stab incision was made through the paratendon with a scalpel blade No.15. A new disposable 3.5 mm motorized synovial resector (Razorcut: Smith and Nephew, USA) was used for each horse. Using ultrasonographic guidance, the inactivated synovial resector was introduced into the core of the tendon in a proximal direction over a length of 7 cm. Once in position, the synovial resector was activated and slowly retrieved in approximately 20s. The paratendon and skin were closed using standard technique. The horses were managed with phenylbutazone (Lisan, Costa Rica) (2.2 mg/kg bwt p.o. twice daily) and penicillin-streptomycin (Pen-Strep: Norbrook, Ireland) (1 ml/25 kg bwt i.m. once daily) 1 hour pre-operatively and 3 days post-operatively. During the first 3 weeks, the animals were box-rested and the distal limbs were immobilized using a regularly changed Robert Jones bandage. From week 4 onwards, a controlled exercise program, based on a previously described protocol (Bosch et al., 2010) was initiated (Table 1).

ACP treatment and sampling protocol

Intralesional treatment was performed 1 and 2 weeks post-surgery. Ten milliliters of whole blood without anticoagulant were aseptically withdrawn from the left jugular vein directly

to the ACP kits. The samples were centrifuged at 189 g for five minutes. The animals were sedated using xylazine (Procin Equus: Pisa, Mexico) (1.1 mg/kg bwt i.v.). The injection site was aseptically prepared and desensitized using 1 ml of subcutaneous lidocaine (Faryvet, Costa Rica). Using ultrasonographic guidance, 2.5 ml of either ACP or sterile saline solution were injected into the core of lesions by a clinician blinded to treatment. The tendons were injected, once per treatment session, using a 20G × 1½ inch needle. The procedure was performed on weight-bearing and the needle was introduced in a longitudinal plane, in a plantaroproximal-dorso-distal direction, aiming at the proximal third of the lesions. Assignment of the ACP-treated limb in each fore and hindlimb pair was random. The procedure was repeated on week 2, therefore freshly prepared ACP was also used for the second intra-tendinous injection.

Cell count and growth factor quantification

The remaining ACP was divided in four to five 0.5 ml EDTA vials. One fresh 0.5 ml ACP aliquot together with a whole blood sample from each animal were examined using an hematology analyzer (Poch100-i: Sysmex, Japan). The rest of the ACP aliquots from the treatment sessions on weeks 1 and 2 and one plasma sample of each animal from the session on week 1 were frozen at -20°C until the active concentrations of PDGF-BB and TGF-β were quantified using sandwich ELISA (Quantikine: R&D Systems, USA).

Clinical assessment

The vital parameters, weight bearing, presence of lameness at walk, local swelling and sensitivity were monitored daily throughout the study. Twenty-four weeks following lesion induction, the lameness was graded using the AAEP lameness score (24) and tendon tenderness was classified as normal, mild, moderate and severe.

Gray-scale ultrasonographic evaluation

A linear multi-frequency probe set at 10 MHz (DP 3300 Vet: Mindray, China) and a silicone standoff pad were used to perform the ultrasonographic examinations of the SDFT lesions at 1, 2, 4, 6, 10, 15 and 24 weeks post-surgery. The limbs were divided in transverse and longitudinal zones as described in the literature (Rantanen et al. 2011) and the

distance distal to the accessory carpal bone or calcaneal tuberosity was recorded for each zone. Re-examinations of every zone in each pair of fore- and hindlimbs were performed at the same distances. A semi-quantitative scoring system was used to grade the echogenicity and fiber alignment of the lesions (Rantanen et al. 2011). The lesion length (LL) was defined as the length from the most proximal to the most distal aspect of the lesion. The total tendon cross-sectional area (TT-CSA) was calculated summing the CSA of the SDFT in 6 different zones (1A to 3B or 2A to 4B). The total lesion cross-sectional area (TL-CSA), total echo-score (T-ES) and total fiber alignment score (FAS) of transverse zones presenting a lesion were calculated for each tendon summing the values of each parameters to get total values. The total lesion percentage (TL-%) was calculated as follows: $(TL-CSA/TT-CSA) \times 100$ (Rantanen et al. 2011). A clinician blinded to treatment performed the data acquisition, measurements and scoring of the images (RJE).

Intra-tendinous vascularization assessment

The intra-tendinous vascularization was scored using the technique reported by Bosch and others (2011a). Color Doppler Ultrasound (CDU) scans were performed 24 weeks post-surgery. The limbs were scanned in flexed position to relax the tendinous structures and therefore avoid the collapse of intra-tendinous vessels due to mechanical forces. The images were obtained using a multi-frequency linear array probe set at 10 MHz and machine settings suitable for low flow vessel detection (VEL/6.2 MHz; 0 Db; 1,099 KHz PRF) (Acuson Antares: Siemens, Germany). The lesions were localized and scanned from lateral to medial on the longitudinal plane. The image sequences of the each scan were stored and the frame with the highest vascularization was subjectively selected and then scored. Data acquisition and vascularization grading was performed by a clinician blinded to treatment (RJE).

Sample harvesting, handling and shipping

After 24 weeks the horses were euthanized. The animals were induced using a combination of xylazine (Procin Equus: Pisa, Mexico) (1.1 mg/kg bwt i.v.) and ketamine-midazolam (Keta-mid: Holliday, Argentina) (2 mg/kg bwt, i.v.); once a deep anesthetic plane was achieved a bolus of an oversaturated magnesium sulphate solution (1 g/kg bwt i.v.) was administered. The SDFTs were harvested immediately after the euthanasia and divided in different sections as reported by Bosch and others (Bosch et al. 2010). In all the horses the lesion were inside the paratendon and easily distinguishable from the healthy tendon (Fig 1). In brief, a transverse 1 cm tendon slice was obtained 2 cm proximal to the scar of the stab incision in the paratendon. The core lesions were identified and

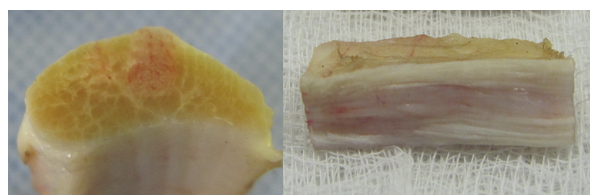


Fig 1. Transverse and longitudinal images of a surgically induced core lesions in the SDFT 24 weeks post-surgery.

Table 1 Exercise protocol of the horses after the lesion induction of the superficial digital flexor tendons

Week Post-Surgery	Walk (min/day)	Trot (min/day)
1-3	-	-
4-6	10	-
7-10	20	-
11-14	30	-
15-20	40	-
21-22	35	5
23-24	30	10

a 4 mm punch, directed longitudinally, was used to harvest injured tissue only. These samples were divided in 3 sections that were lyophilized for 24 h using a vacuum freeze-dryer and then used to perform the biochemical analysis. Proximal to the aforementioned tendon slice, a 3 cm segment was harvested and divided through the center of the lesion in two longitudinal sections. The half used for biomechanical tests was initially frozen at -80°C , then shipped to the laboratories using a dry shipper (MVE Vapor Shipper: Chart Industries, USA) at approximately -150°C and subsequently stored at -80°C until further processing. The other half used for histological evaluation was fixed in 4% formalin for 48 h, placed in 96% ethanol for 5 days (Bosch et al. 2010). These samples were then sequentially transferred through a series of solutions of increasing isopropyl alcohol concentration and then embedded in paraffin blocks.

Glycosaminoglycans and DNA quantification

The lyophilized tendon segments were papain digested (0.1 IU/mg of dwt) at 56°C for 12 hours. A dilution of the papaine digest of each tendon was used to perform the GAG and DNA assays. The quantification of the sulphated GAGs was performed using the 1,9-dimethylmethylene blue dye assay (Farndale et al. 1982). Shark chondroitin sulphate was used as a standard (0–100 g/ml). After an incubation period, the plates were assessed on a microplate reader (VersaMax: Molecular Devices, USA). Total DNA was quantified by means of the reaction with fluorescent dye Hoechst 33258 (Kim et al. 1988). Salmon sperm DNA was used as a standard (0–20 g/ml). The luminescence was measured using a fluorescence spectrometer (LS-50B: Perkin Elmer, USA). In both cases the final results were expressed as g/mg of dry weight tendon.

Degraded collagen, total collagen, and cross links quantification

The tendon samples were processed with α -chymotrypsin to digest the denatured collagen (Lin et al. 2005). Hydroxyproline (Hyp) concentrations in the supernatant (containing the degraded collagen) were determined after the reaction with chloramine T and dimethylaminobenzaldehyde (Reddy and Enwemeka 1996). Results were calculated as previously described and expressed as percentage of degraded collagen (Lin et al. 2005). After the α -chymotrypsin digest, the tendon explants (containing the intact collagen) were hydrolyzed at 110°C for 24 h. The samples were vacuum dried for 24 h, diluted in ultrapure water and centrifuged at 13,000 g for 20 min. The obtained supernatant was submitted to mass spectrometry (MS), to determine the concentrations of hydroxyproline (Hyp), hydroxylsypyrindoline (HP) and lysypyrindoline (LP) using a technique reported by Bosch and others (2010). For calculation of the total collagen the Hyp content in the α -chymotrypsin digest supernatant was summed to the Hyp of the explants measured with the MS.

Pyrrole quantification

Pyrrole was quantified using an adaptation of a previously reported method (Thorpe et al. 2010). The freeze-dried tis-

ues were minced, suspended in a pepsin/HCl solution and digested in a water bath at 45°C for 36 h. Thereafter the samples were centrifuged at 12,000 g for 15 min and 200 μl of supernatant were mixed with 40 μl of Ehrlich's Reagent (4-dimethylaminobenzaldehyde, perchloric acid and deionized water) in a microplate. The samples were incubated at room temperature for 10 min and the absorbance was measured at 558 nm and 650 nm (non-related wavelength) in a microplate reader (VersaMax, Molecular Devices, USA). The pyrrole concentrations were calculated by comparison with a reference line prepared mixing 200 μl of 1-methyl-pyrrole (0–20 mol/l) with 40 μl of Ehrlich's Reagent. Results were expressed as mol per mol of collagen.

Biomechanical assessment

The biomechanical properties of the tendon samples were assessed using a modification of the method reported by Bosch and others (2010). The samples were thawed at room temperature. Longitudinal segments with an approximate cross section of 4 mm^2 and a length of 3 cm were cut from the core lesion of each tendon sample with a cutting device consisting of four disposable high profile microtome blades (Feather: Safety Razor, Japan) at distances of 2 mm. A material testing machine (AX M250–2.5 kN: Testometric Company, UK) was used for failure testing. Sand paper was placed between the ends (proximal and distal) of the tendon sample and the clamps of the machine to decrease slippage. Once in position, the depth and width of the midsection of each sample were measured with a 0.01 mm resolution electronic caliper in a transverse plane to calculate cross-sectional area. The selected segments were tensed and preconditioned at 1 Hz and 3% strain for seven cycles and then tested to failure at a speed of 6 mm/min. The force at failure (F_{max}) and the stress-strain curve were determined for every sample. In each case the ultimate tensile strength (UTS) was calculated (F_{max} /tendon cross-sectional area) and the elastic modulus (EM) deduced from the slope of the linear part of the curve (Bosch et al. 2010).

Histology

Longitudinal 5 mm thick tendon sections were stained with Masson's Trichrome (Artisan: Dako, Denmark). When using this commercial histochemistry staining, the organized tendon collagen was stained red and reparative tissue blue, as previously reported by Cadby and others (2013). Microphotographs of five consecutive fields of view (1x magnification) from different locations of each tendon samples were stored. At this magnification the complete thickness of the tendon section was observable in each microphotograph. An image manipulation software (Gimp 2.8: GNU Project, USA) was used to increase the contrast of the pictures. The red/blue ratio of each histological section was calculated using an image-processing package (Fiji / ImageJ: National Institute of Health, USA). Briefly, the images were assessed setting a threshold that allowed the isolation of the different stained areas in the histological section. Thereafter, the areas of interest (red/blue) were measured (Jensen 2013). The ratio between them calculated was calculated per image and then the average red/blue ratio of the five images of each sample was calculated. The aforementioned color ratio reflects the ratio

between organized and reparative tissue and therefore the degree of damage presented in the tendon.

Statistical analysis

The data was analyzed using Excel (Microsoft Corporation, USA) and Graph Pad Prism 6 (GraphPad Software, USA). The D'Agostino-Pearson test was used to determine the data distribution. A paired Student's t-test was used to analyze the CDU vascularization score and the biochemical, biomechanical and histological parameters. After passing normality tests, the sonographic measurements were evaluated with repeated measures two-way ANOVA followed by a Bonferroni's multiple comparison test. The sonographic scores showed a nonparametric distribution and therefore a Friedman test followed by Dunn's multiple comparison test was applied. The significance level was set at $p \leq 0.05$. Results were reported as mean \pm SD.

Results

Cell count and growth factor quantification

There was no difference in platelet counts between the ACP and whole blood ($P = 0.85$), but there was a significant decrease of WBC counts in ACP (28.8 times). The TGF- concentrations in ACP were not significantly increased when compared to blood plasma ($P = 0.49$), but levels of PDGF-BB were significantly higher (6.1 times) (Table 2).

Clinical assessment

After lesion induction the horses bear weight normally, were not lame at walk and the SDFT presented a moderate to severe tenderness at palpation. No post-surgical complications were noted. After 24 weeks, two horses presented a grade 2/5 lameness (one forelimb and one hindlimb) and were therefore hand-walked for 10 min per day until the end of the study. The horse with the forelimb lameness presented mild tendon tenderness in the lame forelimb (ACP treated) at week 24. In the case of the hindlimb (saline treated), the SDFT showed no tenderness and no further pathological changes that could explained the lameness were found.

Ultrasonographic assessment

All horses developed core lesions that presented ultrasonographic appearance of SDFT naturally occurring injuries

(Fig 2). The grey-scale ultrasonographic parameters evaluated throughout the study didn't show any significant differences (Fig 3–4). Twenty-three weeks after treatment, the ACP treated tendons presented a higher color Doppler vascularization score (2.62 ± 0.91) when compared to saline treated

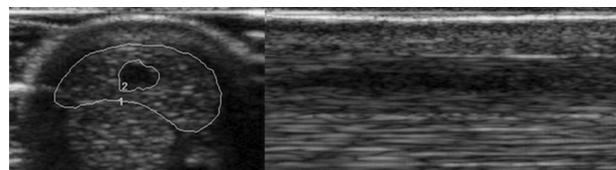


Fig 2 Transverse and longitudinal ultrasonographic images of a surgically induced core lesion in the SDFT 15 days post-surgery.




Fig 3. Gray-scale ultrasonography measurements (mean \pm SD) of autologous conditioned plasma (ACP) and saline-treated surgically induced core lesions in the superficial digital flexor tendon (SDFT) over a 24-week period. (a) Total lesion cross-sectional area (TL-CSA) (b) total tendon cross-sectional area (TT-CSA) (c) total lesion percentage (TL-%) and (d) lesion length (LL).

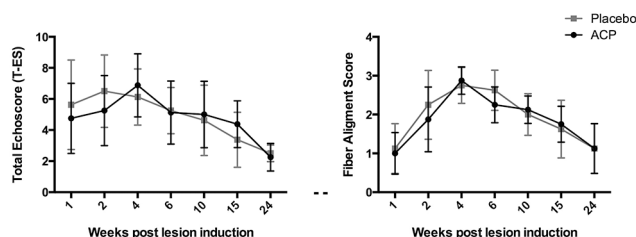


Fig 4 Gray-scale ultrasonography semi-quantitative scores (mean \pm SD) of autologous conditioned plasma (ACP) and saline-treated fore- and hindlimb surgically induced core lesions in the superficial digital flexor tendon (SDFT) over a 24-week period. (a) Total echoscore (T-ES) and (b) fiber alignment score (FAS).

Table 2 Hematological parameters in whole blood and ACP and growth factor concentration in conventional plasma and ACP

Parameter	Average		p-Value
	Whole Blood (n=16)	ACP (n=16)	
Platelets ($\times 10^3 / \mu\text{L}$)	165.3 ± 51.6	162.0 ± 43.6	0.79
Leukocytes ($\times 10^3 / \mu\text{L}$)	9.8 ± 2.6	0.34 ± 0.18	$< 0.0001^*$
	Plasma (n=8)	ACP (n=16)	
TGF- β - ng/ml	8.134 ± 1.051	8.752 ± 2.330	0.49
PDGF-BB - ng/ml	0.066 ± 0.069	0.405 ± 0.194	0.0001^*

TGF, transforming growth factor; PDGF, platelet derived growth factor. * $p \leq 0.05$

tendons (2.00 ± 1.30). Nevertheless, this difference showed only a significant trend ($P = 0.09$).

Biochemical assessment

The ACP treated tendons presented a significantly lower GAG content, when compared to placebo ($P \leq 0.05$). Other compositional parameters did not differ significantly (Table 3).

Biomechanical assessment

Neither the ultimate tensile strength ($P = 0.93$) nor the elastic modulus ($P = 0.13$) differed significantly, when comparing ACP and placebo. One set of data was lost since it was accidentally not stored in the system drive (Table 3).

Histology

The red (organized tissue)/blue (reparative tissue) ratio of microphotographs of five consecutive fields of view of the tendon histological sections stained with Masson's Trichrome showed no significant difference between treatments ($P = 0.95$) (Table 3).

Discussion

Our results indicate that ACP treatment in surgically induced core lesions has a limited influence on tendon healing when compared with saline. In this study, the majority of the ultrasonographic, biochemical, biomechanical and histological parameters showed no significant differences between treatments. Nevertheless, the significant decrease of sulphated GAGs in the ACP treated tendons can be interpreted as a limited, but possibly beneficial, effect on tendon healing.

There are conflicting opinions about the role of leukocytes in blood products used to treat tendinopathy and how they affect tendon healing (McCarrel et al. 2012, Sundman et al. 2011, Everts et al. 2006). There are indications, that in vivo, the leukocytes may have positive effects, such as promote healing, modulate the immune response, anti-inflammatory

action and release of anti-microbial substances (Everts et al. 2006). On the other hand, recent studies have claimed that platelet concentrates with reduced leukocyte concentration might be a suitable option for improving tissue repair, since high leukocyte counts in PRP induce an increase in the production of catabolic and inflammatory cytokines (McCarrel et al. 2012, Sundman et al. 2011). It has been hypothesized that this feature might play a negative role on tendon healing, stimulating more scar tissue formation (McCarrel et al. 2012). The ACP without anticoagulant used in this study showed a significant reduction of the WBC counts, but no measurable increase of the platelet counts. Nonetheless, Wright stains performed on several smears of ACP samples showed extensive platelet aggregation. Due to this finding, we believe that the lack of initial anticoagulant in ACP kits caused a sequestration of the platelets in the aggregates, explaining the relatively low platelet counts in the ACP as the hematology analyzer will have been unable to count the platelets accurately under these circumstances. This hypothesis is also supported by the fact that the PDGF-BB values were significantly increased in the ACP samples, which can only be explained by concentration of the platelets. On the other hand, recent studies suggest that the ACP kit might not be as efficient concentrating platelets as it was previously reported (Hessel et al. 2014). This might be an easier explanation for the low platelet counts, but would not explain the increase in PDGF-BB concentration. However, our study can not be directly compared to Hessel's since ACD-A was not used in the ACP kits. Interestingly, other studies have used ACD-A in the ACP kits (Kissich et al. 2012), but in spite of the usage of anticoagulants an important variability in the average platelet concentration was seen, when compared to the data published by Hessel and others (2014).

This study used ACP without anticoagulant, as it has been shown that growth factor concentrations are higher in serum than in anticoagulated blood (Zimmermann et al. 2005). Interestingly, the PDGF-BB concentrations achieved in this study were lower and the TGF- β were higher (but not significantly higher than conventional plasma) than the reported values using anticoagulant citrate dextrose solution A (ACD-A) (Hessel et al. 2014, Kissich et al. 2012). Several studies have

Table 3 Biochemical, biomechanical and histological parameters of ACP and Placebo treated SDFTs 23 weeks after treatment.

Parameters	Treatment Group		p-Value
Biochemical	Placebo (n=8)	ACP (n=8)	
GAG - $\mu\text{g}/\text{mg}$ dwt	37.21 ± 24.78	26.98 ± 14.86	0.05*
DNA - $\mu\text{g}/\text{mg}$ dwt	3.42 ± 0.69	3.32 ± 1.32	0.81
Total Collagen - mg/mg dwt	0.63 ± 0.01	0.70 ± 0.10	0.34
Degraded Collagen - %	0.89 ± 0.61	0.93 ± 0.38	0.91
Pyrrole - mol/mol collagen	0.053 ± 0.01	0.043 ± 0.01	0.11
HP - mol/mol collagen	0.52 ± 0.09	0.59 ± 0.16	0.19
LP - mol/mol collagen	0.022 ± 0.005	0.020 ± 0.006	0.51
Biomechanical	Placebo (n=7)	ACP (n=7)	
Ultimate Tensile Stress – MPa	15.20 ± 9.44	14.89 ± 4.57	0.94
Elastic Modulus- GPa	0.147 ± 0.07	0.103 ± 0.03	0.13
Histology	Placebo (n=8)	ACP (n=8)	
Masson's Trichrome Red / Blue Ratio – Decimals	0.164 ± 0.087	0.161 ± 0.092	0.95

GAG, glycosaminoglycans; HP, hydroxylysylpyridinoline; LP, lysylpyridinoline * $p \leq 0.05$

demonstrated that EDTA may alter the determination of the growth factor concentration (Zimmermann et al. 2005, Biellohuby et al. 2013). In this study, the storage of the ACP samples in EDTA vials may have affected the accuracy of the determination of the growth factor concentrations. Nevertheless, as conventional plasma and ACP samples were treated identically, there is no doubt about the highly significant increase in PDGF-BB concentration in ACP samples. Even though there was a significant difference in the PDGF-BB concentration, these results were significantly lower when compared to previously reported values (Hessel et al. 2014, Kissich et al. 2012). Interestingly, a recent study suggests that ACP is apparently not as efficient concentrating PDGF-BB and TGF- α as it was previously reported (Hessel et al. 2014), this might suggest that the growth factor differences found in these 3 studies could have been caused by a low repeatability of the ACP kit when using horse blood. This is especially true when comparing the values reported by Hessel and others (2014) and Kissich and other (2012), where ACD-A and a very similar processing protocol were used.

Glycosaminoglycans (GAGs) are polysaccharides that are usually covalently attached to core protein, forming macromolecules known as proteoglycans (Esko 1999). In tendons, they are in part involved in the regulation of the collagen fibrillogenesis, affecting fibril size and formation rate (Cribb

and Scott 1995). Moreover, these molecules contribute to the biomechanical and structural properties of the extracellular matrix (Parkinson et al. 2011). The role of GAG accumulation after tendon damage is seen controversial in the literature. Previous studies in humans and equines indicate that degenerated tendon regions present higher concentrations of sulphated GAGs (Birch et al. 1998, Parkinson et al. 2010). Synthesis and accumulation of these molecules is usually correlated to an increased cellular metabolism within injured areas in the tendon (Parkinson et al. 2010) and a marked increase of small collagen fibers, decreasing the mechanical properties of tendons and ligaments (Halper et al. 2006). On the other hand, a recent study using blood products for the treatment surgically induced core lesions interpreted the increase of intralesional sulphated GAG concentration as a positive feature of tendon healing (Bosch et al. 2010). The GAG values found in this study were significantly higher than the average GAG content reported for normal equine SDFTs in the metacarpal region (Lin et al. 2005), but similar to what has been reported for SDFT core lesions 24 weeks after induction (Bosch et al. 2010). The fact that the ACP treated tendons showed significantly less sulphated GAGs suggests that the treatment might have positively affected the intra-tendinous cellular metabolism, which may thus have a beneficial effect on the characteristics of both the non-collagenous and collagenous matrix of the tendons. The difference in the GAG




Fig 5 (A) Example of an histological section of a placebo treated tendon stained with Masson's Trichrome. The red areas mainly represent organized collagen and the blue reparative tissues (B) Manipulation of the image to increase contrast using an image manipulation software (Gimp)q. (C-D) Determination of the percentage of the red and blue stained regions for the calculation of a red/blue ratio using an imaging processing package (Fiji/ImageJ)r.

content may also be interpreted as a faster tendency towards normalization of this parameter when compared to control treated SDFTs. Nonetheless, this interpretation might be daring, without a direct comparison of the GAG content between injured and healthy tendon sections and without having any other significant difference in the rest of the biochemical parameters. The biomechanical tests performed in this study could not demonstrate a significant difference between the mechanical properties of the ACP and saline treated tendons. Therefore, it is most likely that the significant difference in GAG content found in this study does not play a major role affecting the biomechanical characteristics of the tendons.

Tendon lesions present an increased blood flow after acute injury, allowing cell recruitment and providing humoral mediators, growth factors and nutrients needed for adequate lesion healing (Yang et al. 2012). There is a general consensus that normal equine tendons present no detectable intra-tendinous blood flow when evaluated with color or power Doppler ultrasound (Bosch et al. 2011, Kristoffersen et al. 2005). The role of persistent intra-tendinous vascularization is seen controversial in the literature. Traditionally, persistent vascularization has been interpreted as a sign of inadequate healing and incomplete repair (Kristoffersen et al. 2005, Murata et al. 2012), but it is not clear in the literature for how many months the vascularization should be visible, so that it can be called persistent. On the contrary, Bosch and others (2011a) reported that 23 weeks after intra-tendinous PRP treatment, the PRP treated tendons presented a higher CDU vascularization score than saline treated tendons. This finding was interpreted as a positive feature of the therapy and it was suggested that this might be in part responsible for the improved quality of the repaired tendon tissues obtained in this study. Twenty-three weeks after treatment, the ACP treated tendons presented a borderline significant trend towards a higher vascularization score when compared to the saline treated structures. The increased CDU vascularization score is probably correlated to an increased neovascularization, most likely stimulated by the growth factors injected in the tendon lesion. This result might be interpreted as positive feature of this therapeutical approach, since adequate vascularization is a prerequisite for optimal progress of the acute and proliferative phases of healing (Bosch et al. 2011a). However, future studies must investigate the risks of inducing persistent vascularization when using intra-tendinous platelet concentrates and the role that the persistent vascularization plays in chronic equine tendinopathies.

The Masson's Trichrome stain used in this study stained the organized tendon fibers red, whereas the reparative tissue blue, as previously reported (Cadby et al. 2013). This pattern was consistent in all samples, allowing making a clear distinction between blue and red areas. This staining technique, in conjunction with the imaging analysis system, proved very helpful for an objective global assessment of the tendon structure (Fig 5).

It has been suggested that leukocyte-reduced platelet concentrates might be superior than PRP stimulating tendon healing, since persistent inflammation incited by the WBC may result in scar tissue formation (McCarrel et al. 2012). Comparing our results to those of other studies using similar

models (Bosch et al. 2010, Bosch et al. 2011a, Bosch et al. 2011b), it seems that PRP has a more profound effect on tendon healing than ACP without anticoagulant. On the other hand, even though PRP showed several positive effects on tendon healing, it is still questionable if the increased intra-tendinous vascularization, sulphated GAG content and cellularity found 23 weeks after the first treatment can be interpreted as beneficial, since these features have been previously correlated to poor tendon repair (Godwin et al. 2012, Kristoffersen et al. 2005, Birch et al. 1998). Therefore, it is of paramount importance to continue studying the in vivo effect of the different platelet preparations to determine which is more efficient normalizing biomechanical, biochemical and histological parameters towards those levels found in healthy tendons.

There are limitations to this study. Even though this surgical tendinopathy model created lesions emulating naturally-occurring SDFT core lesions (Cadby et al. 2013), the fiber disruption caused by the synovial resector does not replicates the degenerative process that is believed to precede the majority of the natural clinical injuries (Birch et al. 1998). A period of 24 weeks is certainly not long enough to evaluate the end stage tendon healing, since the final maturation of tendon repair takes approximately one year (Silver et al. 1983). Histological evaluations of tendon healing have been traditionally performed using semi-quantitative scores (Bosch et al. 2010). Aiming at objectivizing this evaluation, an image-processing package was used to analyze the microphotographs of the histological sections in this study. The fact that only this technique was used might have caused a loss of valuable subjective information. Even though the normal biochemical parameters of the SDFT have been already published (Lin et al. 2005), processing healthy regions of the tendons would have allowed a more accurate comparison between the lesion site and the normal tissues. The use of a multi-limb model might have affected the loads on the injured tendons and hence the healing process. However the horses in this study never presented overt signs of pain or showed an abnormal weight bearing, therefore is not likely that this factor played a role in the healing of the lesions.

Conclusions

Our study indicates that 2 intra-tendinous ACP treatments (without anticoagulant), during the proliferative phase of healing, in surgically induced SDFT core lesions, have a limited effect on tendon healing when comparing ultrasonographic, biochemical, biomechanical and histological parameters with the control treatment. Long-term placebo controlled clinical trials with more horses are warranted to determine if this effect is clinically significant.

Conflict of interests

Arthrex Inc. financed approximately 30% of the costs of this study, but it was not involved in the collection, analysis or interpretation of the data or in the publication of the manuscript. The authors have no competing interests that could influence the content of this paper.

Acknowledgements

The authors are grateful to J. Vargas, J.M. Estrada-McDermott, C. Murillo and the rotation students from the Large Animal Hospital and the Regenerative Therapy Unit, School of Veterinary Medicine, National University, Costa Rica for all their efforts during the course of this study, to R. Estrada, G. León and M. Herrera from the Clodomiro Picado Institute, Costa Rica for their help with the sample preparation and ELISA's, to J. Coen for performing the hematological processing of the samples, to A. Castillo for facilitating sample export and to Prof. H. Weinans from the Orthopedic Department, Erasmus MC for the advice with the biomechanical test. We would also like to thank Alimentos Concentrados Montes de Oro, Costa Rica and 3M, Costa Rica for the donation of concentrates and bandaging tape for this investigation.

References

- American Association of Equine Practitioners. Definition and classification of lameness. In: Guide for Veterinary Service and Judging of Equestrian Events. Lexington, KY, USA; American Association of Equine Practitioners, 1991
- Avella C. S., Ely E. R., Verheyen K. L., Price J. S., Wood J. L., Smith R. K. (2009) Ultrasonographic assessment of the superficial digital flexor tendons of National Hunt racehorses in training over two racing seasons. *Equine Vet. J.* 41, 449-454
- Bielohuby M., Popp S., Bidlingmaier M. (2013) Influence of pre-analytical conditions on the measurement of components of the GH/IGF axis in rats. *Growth Horm. IGF Res.* 23, 141-148
- Birch H. L., Bailey A. J., Goodship A. E. (1998) Macroscopic 'degeneration' of equine superficial digital flexor tendon is accompanied by a change in extracellular matrix composition. *Equine Vet. J.* 30, 534-539
- Bosch G., Moleman M., Barneveld A., van Weeren P. R., van Schie H. T. (2011a) The effect of platelet-rich plasma on the neovascularization of surgically created equine superficial digital flexor tendon lesions. *Scand. J. Med. Sci. Sports* 21, 554-561
- Bosch G., van Weeren P. R., Barneveld A., van Schie H. T. (2011b) Computerised analysis of standardised ultrasonographic images to monitor the repair of surgically created core lesions in equine superficial digital flexor tendons following treatment with intratendinous platelet rich plasma or placebo. *Vet. J.* 187, 92-98
- Bosch G., van Schie H. T., de Groot M. W., Cadby J. A., van de Lest C. H., Barneveld A., van Weeren P. R. (2010) Effects of platelet-rich plasma on the quality of repair of mechanically induced core lesions in equine superficial digital flexor tendons: A placebo-controlled experimental study. *J. Orthop. Res.* 28, 211-217
- Boswell S. G., Cole B. J., Sundman E. A., Karas V., Fortier L. A. (2012) Platelet-rich plasma: a milieu of bioactive factors. *Arthroscopy* 28, 429-439
- Cadby J. A., David F., van de Lest C., Bosch G., van Weeren P. R., Snedeker J. G., van Schie H. T. (2013) Further characterisation of an experimental model of tendinopathy in the horse. *Equine Vet. J.* 45, 642-648
- Crevier-Denoix N., Collobert C., Pourcelot P., Denoix J. M., Sanaa M., Geiger D., Bernard N., Ribot X., Bortolussi C., Bousseau B. (1997) Mechanical properties of pathological equine superficial digital flexor tendons. *Equine Vet. J. Suppl.* 23, 23-26
- Cribb A. M., Scott J. E. (1995) Tendon response to tensile stress: an ultrastructural investigation of collagen:proteoglycan interactions in stressed tendon. *J. Anat.* 187, 423-428
- Deans V. M., Miller A., Ramos J. (2012) A prospective series of patients with chronic Achilles tendinopathy treated with autologous-conditioned plasma injections combined with exercise and therapeutic ultrasonography. *J. Foot Ankle Surg.* 51, 706-710
- Dyson S. J. (2004) Medical management of superficial digital flexor tendonitis: a comparative study in 219 horses (1992-2000). *Equine Vet. J.* 36, 415-419
- Esko J. D. (1999) Proteoglycans and Glycosaminoglycans. In: Varki A., Cummings R., Esko J. D. (ed): *Essentials of Glycobiology*, vol 2, Cold Spring Harbor Laboratory Press, New York, <http://www.ncbi.nlm.nih.gov/books/NBK1900>
- Estrada R. J., van Weeren P. R., van de Lest C. H., Boere J., Reyes M., Ionita J. C., Estrada M., Lischer C. J. (2014) Comparison of healing in forelimb and hindlimb surgically induced core lesions of the equine superficial digital flexor tendon. *Vet. Comp. Orthop. Traumatol.* 27, 358-365
- Everts P. A., Hoffmann J., Weibrich G., Mahoney C. B., Schönberger J. P., van Zundert A., Knappe J. T. (2006) Differences in platelet growth factor release and leucocyte kinetics during autologous platelet gel formation. *Transfus. Med.* 16, 363-368
- Farndale R. W., Sayers C. A., Barrett A. J. (1982) A direct spectrophotometric microassay for sulphated glycosaminoglycans in cartilage cultures. *Connect Tissue Res.* 9, 247-248
- Gibson K. T., Burbidge H. M., Pfeiffer D. U. (1997) Superficial digital flexor tendonitis in thoroughbred race horses: outcome following non-surgical treatment and superior check desmotomy. *Aust. Vet. J.* 75, 631-635
- Godwin E. E., Young N. J., Dudhia J., Beamish I. C., Smith R. K. (2012) Implantation of bone marrow-derived mesenchymal stem cells demonstrates improved outcome in horses with overstrain injury of the superficial digital flexor tendon. *Equine Vet. J.* 44, 25-32
- Halper J., Kim B., Khan A., Yoon J. H., Mueller P. O. (2006) Degenerative suspensory ligament desmitis as a systemic disorder characterized by proteoglycan accumulation. *BMC Vet. Res.* 2:12
- Hessel L. N., Bosch G., van Weeren P. R., Ionita J. C. (2014) Equine autologous platelet concentrates: A comparative study between different available systems. *Equine Vet. J. doi: 10.1111/evj.12288*. [Epub ahead of print]
- Jensen E. C. (2013) Quantitative Analysis of Histological Staining and Fluorescence Using ImageJ. *Anat. Rec. (Hoboken)*. 296, 378-381
- Kasashima Y., Takahashi T., Smith R. K., Goodship A. E., Kuwano A., Ueno T., Hirano S. (2004) Prevalence of superficial digital flexor tendonitis and suspensory desmitis in Japanese Thoroughbred flat racehorses in 1999. *Equine Vet. J.* 36, 346-350
- Kim Y. J., Sah R. L., Doong J. Y., Grodzinsky A. J. (1988) Fluorometric assay of DNA in cartilage explants using Hoechst 33258. *Anal. Biochem.* 174, 168-176
- Kissich C., Gottschalk J., Lochmann G., Einspanier A., Böttcher P., Winter K., Brehm W., Ionita J. C. (2012) Biochemische Eigenschaften des equinen Autologous Conditioned Plasma (ACP). *Pferdeheilkunde* 28, 258-267
- Kristoffersen M., Ohberg L., Johnston C., Alfredson H. (2005) Neovascularisation in chronic tendon injuries detected with colour Doppler ultrasound in horse and man: implications for research and treatment. *Knee Surg. Sports Traumatol. Arthrosc.* 13, 505-508
- Lin Y. L., Brama P. A., Kiers G. H., DeGroot J., van Weeren P. R. (2005) Functional adaptation through changes in regional biochemical characteristics during maturation of equine superficial digital flexor tendons. *Am. J. Vet. Res.* 66, 1623-1629
- McCarrel T. M., Minas T., Fortier L. A. (2012) Optimization of leukocyte concentration in platelet-rich plasma for the treatment of tendinopathy. *J. Bone Joint Surg. Am.* 94, 1-8
- Murata D., Misumi K., Fujiki M. (2012) A preliminary study of diagnostic color Doppler ultrasonography in equine superficial digital flexor tendonitis. *J. Vet. Med. Sci.* 74, 1639-1642
- Murray R. C., Dyson S. J., Tranquille C., Adams V. (2006) Association of type of sport and performance level with anatomical site of orthopaedic injury diagnosis. *Equine Vet. J. Suppl.* 36, 411-416
- O'Meara B., Bladon B., Parkin T. D., Fraser B., Lischer C. J. (2010) An investigation of the relationship between race performance and superficial digital flexor tendonitis in the Thoroughbred racehorse. *Equine Vet. J.* 42, 322-326

- Parkinson J., Samiric T., Ilic M. Z., Cook J., Handley C. J. (2011) Involvement of Proteoglycans in Tendinopathy. *J. Musculoskelet. Neuronal Interact.* 11, 86-93
- Parkinson J., Samiric T., Ilic M. Z., Cook J., Feller J. A., Handley C. J. (2010) Change in Proteoglycan Metabolism Is a Characteristic of Human Patellar Tendinopathy. *Arthritis Rheum.* 62, 3028-3035
- Rantanen N. W., Jorgensen J. S., Genovese R. L. (2011) Ultrasonographic Evaluation of the Equine Limb: Technique. In: Dyson S. and Ross M. (ed): *Diagnosis and Management of Lameness in the Horse*, vol 2., Elsevier Saunders, Missouri, pp. 183-205
- Reddy G. K., Enwemeka C. S. (1996) A simplified method for the analysis of hydroxyproline in biological tissues. *Clin. Biochem.* 29, 225-229
- Rindermann G., Cislakova M., Arndt G., Carstanjen B. (2010) Autologous conditioned plasma as therapy of tendon and ligament lesions in seven horses. *J. Vet. Sci.* 11, 173-175
- Schramme M., Hunter S., Campbell N., Blikslager A., Smith R. (2010) A surgical tendonitis model in horses: technique, clinical, ultrasonographic and histological characterisation. *Vet. Comp. Orthop. Traumatol.* 23, 231-239
- Silver I. A., Brown P. N., Goodship A. E., Lanyon L. E., McCullagh K. G., Perry G. C., Williams I. F. (1983) A clinical and experimental study of tendon injury, healing and treatment in the horse. *Equine Vet. J. Suppl.* 1, 1-43
- Singer E. R., Barnes J., Saxby F., Murray J. K. (2008) Injuries in the event horse: training versus competition. *Vet. J.* 175, 76-81
- Sundman E. A., Cole B. J., Fortier L. A. (2011) Growth factor and catabolic cytokine concentrations are influenced by the cellular composition of platelet-rich plasma. *Am. J. Sports Med.* 39, 2135-2140
- Thorpe C. T., Stark R. J., Goodship A. E., Birch H. L. (xxxx) Mechanical properties of the equine superficial digital flexor tendon relate to specific collagen cross-link levels. *Equine Vet. J. Suppl.* 38, 538-543
- Waselau M., Sutter W. W., Genovese R. L., Bertone A. L. (2008) Intralesional injection of platelet-rich plasma followed by controlled exercise for treatment of midbody suspensory ligament desmitis in Standardbred racehorses. *J. Am. Vet. Med. Assoc.* 232, 1515-1520
- Williams I. F., Heaton A., McCullagh K. G. (1980) Cell morphology and collagen types in equine tendon scar. *Res. Vet. Sci.* 28, 302-310
- Yang X., Coleman D. P., Pugh N. D., Nokes L. D. (2012) The volume of the neovascularity and its clinical implications in achilles tendinopathy. *Ultrasound Med. Biol.* 38, 1887-1895
- Zhang J., Middleton K. K., Fu F. H., Im H. J., Wang J. H. (2013) HGF mediates the anti-inflammatory effects of PRP on injured tendons. *PLoS One* 8(6):e67303. doi: 10.1371/journal.pone.0067303
- Zimmermann R., Koenig J., Zingsem J., Weisbach V., Strasser E., Ringwald J., Eckstein R. (2005) Effect of specimen anticoagulation on the measurement of circulating platelet-derived growth factors. *Clin. Chem.* 51, 2365-2368